

"Protective effect of *Polyherbal Acetonic extract of Curcuma longa rhizome and Sida spinosa leaves* against Carbon Tetrachloride (CCl₄) induced liver injury in rats"

Mohd Murad Azmi^{1*} Manmeet Singh Saluja¹ Waseem Ahmad Khan² Sakshi Srivastava² Alok Kumar Srivastava²

¹Department of Pharmacy, Monard University, Hapur, U.P, India- 245304.

²Department of Pharmacy, Hygia Institute of Pharmaceutical Education and Research (HIPER), Faizullahganj, Lucknow, U.P, India-226020.

***Corresponding Author: Mohd Murad Azami**

M.Pharm, (Phd), Research scholar, ¹Department of Pharmacy, Monard University, Hapur, U.P, India- 245304

murad.azmi86@gmail.com

Abstract

The objective of the current investigation was to investigate the hepatoprotective effect of *Polyherbal Acetonic extract of Curcuma longa rhizome and Sida spinosa leaves* extracts against carbon tetrachloride (CCl₄)-induced liver injury in rats. The *Polyherbal Acetonic extract of Curcuma longa rhizome and Sida spinosa leaves* were administered orally at a dosage of 150, 300 and 500 mg/kg body weight to Wistar albino rats, with Silymarin serving as the standard. *Polyherbal Acetonic extract* showed a strong hepatoprotective effect by restoration of functional parameters, physical parameters, biochemical parameters and reducing blood enzymes alkaline phosphatase (ALP), and total bilirubin (TBL) in the chosen animal. The chemical contents of the plant include alkaloids, flavonoids, glycosides, steroids, terpenoids, phenolics, and saponins, among others. The overall experimental findings imply that bioactive phytoconstituents, such as flavonoids and alkaloids found in the *Polyherbal Acetonic extract of Curcuma longa rhizome and Sida spinosa leaves*, may be responsible for the plant's substantial hepatoprotective action. Consequently, the findings support the use of *Curcuma longa rhizome and Sida spinosa leaves* as a hepatoprotective agent.

Keywords

Carbon tetrachloride, Hepatoprotective activity, *Curcuma longa rhizome*.

Introduction

Curcuma name was coined by Linnaeus in 1753 in his Species Plantarum. The word likely gets its reference from the Arabic word 'kurkum', which means yellow colour. *Curcuma longa* Roxb. (Family: *Zingiberaceae*) is enduring rhizomatic fragrant herb which is known as Mango ginger and is available from month November to April. Mango ginger (*Curcuma longa* Roxb.) is an antique spice which has morphological resemblance with ginger but it imparts a raw mango flavour. The genus originated in the Indo-Malayan region, and is broadly distributed in the tropics of Asia to Africa and Australia. [1]. In India it is found in regions of West Bengal, Madhya Pradesh, Chattisgarh Orissa, and Uttar Pradesh. It prospers well in wet deciduous woodland regions. Rhizomes of another species *Curcuma longa* (Mango ginger) normally known as Amba Haldi, grown in west Bengal and on the slopes of West coast of India. Mango ginger is grown in regions of Gujarat and discovered wild in pieces of West Bengal, U.P, Karnataka and Tamil Nadu. [2,3], *Curcuma longa* Roxb. is a rhizomatous fragrant spice with a leafy tuft and grows upto height of 60-90 cm. Leaves are long, petiolate, oval lanceolate, tightening at the two closures, glabrous and green on the two sides. [4, 5]. Rhizome is small in size, 3×1 cm, cone like brownish; roots many, some ending in root tubers. Flowers are longer than the bracts, 4.5-5.5 cm; bract 3-4 cm; light yellow. Calyx 1-1.2 cm, 3 lobed at peak, violet dappled, thickly pubescent. Corolla tube light yellow, Seeds 3.5-5 mm long obovate; aril white [6,7,8]. Indian medication utilizes turmeric powder for the treatment of biliary issues, cold and flu, anorexia, hepatic problems, diabetic injuries, rheumatics and sinusitis. The rhizome is very pungent, healing, bitter, laxative, vulnerary anthelmintic, tonic and emollient. It is also used as a medicine in various kapha and vata blood diseases. It is used in the treatment of bronchitis, vertigo, dropsy, skin diseases, elephantiasis, burns, boils, sprains, fevers, swellings, chronic gonorrhoea, bruises, chicken pox, small pox, snake bites, scabies, dyspepsia, ring worm, etc. [9-14]. Here, we tested the efficacy of methanol and hydroethanol extracts of *Curcuma longa* on CCl₄-induced liver damage in rats to see whether they might prevent or lessen the severity of the disease.

Procurement and Authentication of the Plant

The *Curcuma longa* rhizome and *Sida spinosa* leaves were gathered from the surrounding region of NCR, where they were certified by Dept. of Botany, Monard University, UP, India.

Preparation of Polyherbal Acetonic extract of *Curcuma longa* rhizome and *Sida spinosa* leaves

In a Soxhlet apparatus, 500g of poly herbal powdered of *Curcuma longa* rhizome and *Sida spinosa* leaves were extracted with solvent in order to increasing polarity. The materials were concentrated by evaporation [15].

Animals

Wistar albino rats (150-200 g) were procured from Central Drug Research Institute, Lucknow, India. The animals were fed with standard pellet diet (Hindustan lever Ltd. Bangalore) and water *ad libitum*. All the animals were acclimatized for a week before use. The experimental protocols were approved by Institutional Animal ethics Committee after scrutinization. Animals were received the drug by oral gavages tube. All the animals were care of under ethical consideration as per the CPCSEA guidelines with regular inspections of rats. The laboratory conditions duly undertaken by registered veterinary practitioner [16].

Chemicals

All the chemicals and solvents were of analytical grade. Silymarin was obtained as gift sample from Micro Lbs, Goa, India. Standard kits for SGOT, SGPT and ALP etc. were obtained from Span Diagnostics Ltd., India.

Preliminary phytochemical analysis

To determine which phytoconstituents were present in each polyherbal extract, a preliminary phytochemical study was performed.

Toxicity studies

All of the polyherbal extracts were subjected to an acute toxicity test in accordance with OECD 423 guidelines [16]. Research on acute toxicity was conducted on female albino rats. Before administering the extract orally at dosages of 100, 200, and 500mg/kg b.w., the animals were fasted for 24 hours with only water provided, and then monitored for toxic symptoms for up to 72 hours. The therapeutic oral dosage for all extracts was 500 mg/kg body weight.

Carbon tetrachloride induced hepatotoxicity

The rats, of both sexes, were split up into 6 groups of six each. ($n = 6$) [16, 17]

- **Group I (Control):** administered water (5 mililitre/kilogram, p.o.) *o.d.* for nine days.
- **Group II (-ve control):** administered water (5 mililitre/kilogram, p.o.) *o.d.* for nine days, meanwhile on the seventh day, carbon tetrachloride (1 ml/kg in 50% v/v olive oil, s.c.) was given.
- **Group III (+ve control):** administered the normal medicine silymarin (25 mg/kg, p.o.) *o.d.* for nine days, meanwhile on the seventh day, carbon tetrachloride (1 ml/kg in 50% v/v olive oil, s.c.) was given.

- **Group IV and V (Test Sample)** administered *Polyherbal Acetonic extract of Curcuma longa rhizome and Sida spinosa leaves* (300 and 500 mg/kg) *o.d.* for nine days, meanwhile on the seventh day, carbon tetrachloride (1 ml/kg in 50% v/v olive oil, s.c.) was given. On last day, blood was obtained from animals by puncturing retro orbital plexus. Blood samples were allowed to clot for 45 min at room temperature. Serum was separated by centrifugation at 2500 rpm at 30°C for 15 min and utilized for the estimation of various biochemical parameters including SGOT & SGPT [18], ALP [19], serum bilirubin [20] and serum protein [21] After collection of blood samples, the animals were sacrificed under deep ether anesthesia. Morphological parameters like weight of animals, weight of liver have also been used to evaluate the protective effect of the drug. Hepatoprotective chemical causes loss in liver weight/100 gm body weight of rats [22, 23].

Histopathology studies

A portion of liver tissue of all the animal groups was excised and then washed with normal saline. The liver tissues were fixed in 10% buffered neutral formalin for 48 hrs and then with bovine solution for 6 hrs and were then processed for paraffin embedding. By using a microtome, sections of 5 mm thickness were taken and stained with hematoxylin and eosin. These sections were examined under light microscope using a magnification of 100X [24].

Statistical Significance

The results of the study were expressed as mean \pm SEM, n=6. ANOVA [25] was used to analyze and compare the data, followed by Dunnet's [26] test for multiple comparisons.

RESULTS

Chemical testing identified the presence of the phytoconstituents in the different extracts. The findings demonstrate that *Polyherbal Acetonic extract of Curcuma longa rhizome and Sida spinosa leaves* contain the greatest amount of pharmacologically active compounds, such as glycosides, sponins, phytosterols, and flavonoids. As a result, these extracts were chosen for the pharmacological research. The findings are shown in **Table 1**. There was no mortality found amongst the graded dose groups of animals and they did not show any toxicity or behavioural changes at a dose level of 5000 mg/kg. This finding suggests that *Polyherbal Acetonic extract of Curcuma longa rhizome and Sida spinosa leaves* (300 & 500 mg/kg) were safe or non-toxic to rats and hence doses of 500 mg/kg, *p.o.* were selected for the study. All groups of animals tested fell asleep after receiving an intramuscular injection of thiopentone sodium (40 mg/kg). When CCl₄ was administered to rats, the beginning of sleep was significantly delayed (measured in seconds) and the total amount of time spent in sleeping was increased (measured in minutes). Pretreatment with *Polyherbal Acetonic extract of Curcuma longa rhizome and Sida spinosa leaves* (300 & 500 mg/kg, bw, *p.o.*) and silymarin, substantially improved sleep onset but dramatically reduced sleep duration

in rats compared to a CCl₄ treatment group. The outcomes are shown in **Table 2**. An increase in liver weight and liver volume were seen in the CCl₄ treated group, indicating that the livers of these individuals had grown in size. Liver weight was significantly restored in the groups given *Polyherbal Acetonic extract of Curcuma longa rhizome and Sida spinosa leaves* (300 & 500 mg/kg, bw, p.o.) together with silymarin. The findings are shown in **Table 3**. There was a significant elevation in the levels of serum marker enzymes like SGOT, SGPT and ALP content of CCl₄ treated groups, But pretreatment with *Polyherbal Acetonic extract of Curcuma longa rhizome and Sida spinosa leaves* (300 & 500 mg/kg, bw, p.o.) and silymarin (25 mg/kg, p.o.) exhibited an ability to counteract the hepatotoxicity by decreasing serum marker enzymes. The findings are shown in **Table 4**. In CCl₄ treated groups, there was a significant increase in total bilirubin and significant reduction in total protein content. Whereas, pretreatment with *Polyherbal Acetonic extract of Curcuma longa rhizome and Sida spinosa leaves* (300 & 500 mg/kg, bw, p.o.) caused significant reduction in total bilirubin and significant increase in total protein. The findings are shown in **Table 4**.

Histopathological studies of liver also provided a supportive evidence for biochemical analysis. Histological changes such as steatosis (fatty changes in hepatocytes) and perivenular fibrosis were observed in CCl₄ treated (toxic) control group. Both the extracts has prevented these histological changes. The results were showed in **Figure 1**.

Table 1: Preliminary Phytochemical studies of Extracts of *Polyherbal Acetonic extract of Curcuma longa rhizome and Sida spinosa leaves*

Constituents	<i>Polyherbal Acetonic extract of Curcuma longa rhizome and Sida spinosa leaves</i>
Carbohydrate	+
Glycosides	-
Oil and fats	+
Proteins	+
Saponins	-

Phenolic comp. and tannins	+
Phytosterols	+
Alkaloids	+
Gums and mucilage	-
Flavonoids	+

Table 2: Effect of Polyherbal Acetonic extract of *Curcuma longa* rhizome and *Sida spinosa* leaves on functional parameters in CCl₄ induced hepatotoxic rats.

Treatment/ Dose	Onset of sleep(Sec.)	Duration of sleep (Min.)
Normal	159.9 ± 5.01	105.4 ± 3.42
Induced (CCl ₄)	72.01 ± 3.12*	274.5 ± 6.22*
Standard (Silymarin)	156.72 ± 2.14***	131.2 ± 2.31***
PHAECLSS 300 <i>mg/kg</i>	132.20 ± 3.40**	179.12 ± 5.73**
PHAECLSS 500 <i>mg/kg</i>	139.01 ± 5.67***	165.8 ± 4.70***

Values are mean ± SEM, n = 6. (One way ANOVA Followed by Dunnet multiple comparisons test). Statistically significance of ** P<0.01, *** P<0.001, when compared with CCl₄ induced group and * P<0.05, when compared with normal group.

TABLE 3: Effect of Polyherbal Acetonic extract of *Curcuma longa* rhizome and *Sida spinosa* leaves on Physical Parameters in CCl₄ induced hepatotoxic rats.

Treatment/ Dose	Liver Weight	Liver Volume
Normal	7.41 ± 0.21	7.52 ± 0.22
Induced (CCl ₄)	16.96 ± 1.25*	17.01 ± 1.11*
Standard (Silymarin)	8.97 ± 1.11***	9.14 ± 1.72***
PHAECLSS 300 <i>mg/kg</i>	8.64 ± 1.51**	8.35 ± 1.76**
PHAECLSS 500 <i>mg/kg</i>	9.79 ± 1.38***	9.92 ± 1.52***

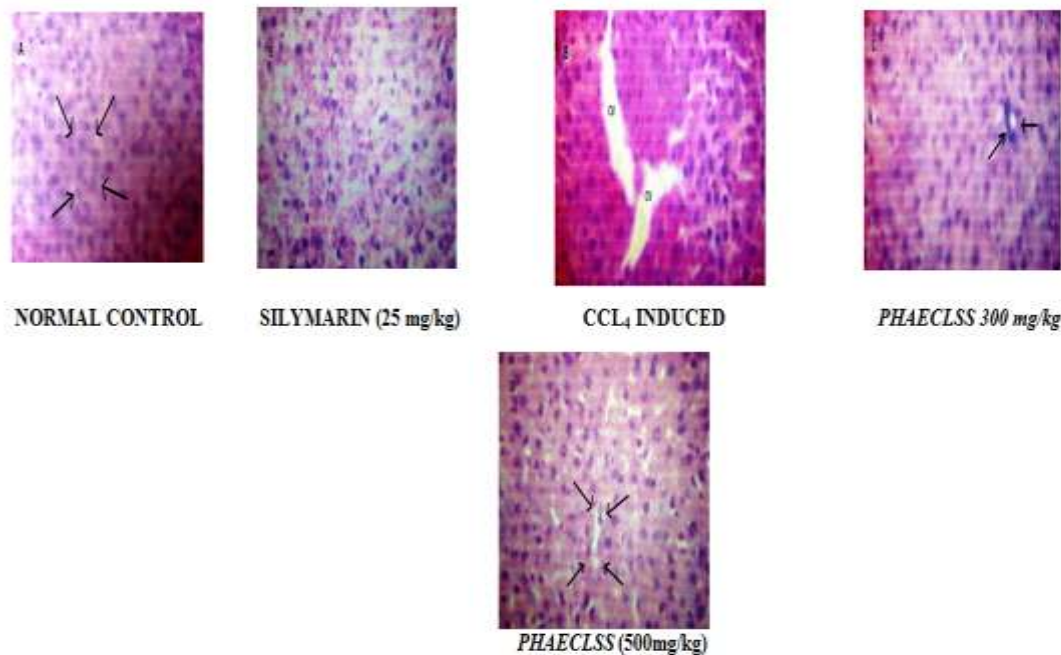
Values are mean ± SEM, n = 6. (One way ANOVA Followed by Dunnet multiple comparisons test). Statistically significance of ** P<0.01, *** P<0.001, when compared with CCl₄ induced group and * P<0.05, when compared with normal group.

Table 4: Effect of Polyherbal Acetonic extract of *Curcuma longa* rhizome and *Sida spinosa* leaves on serum enzyme parameter in CCl₄ induced hepatotoxic rats.

Treatment/ Dose	SGPT U/L	SGOT U/L	ALP U/L	Total Bilirubin (mg/dl)	Total Protein (gm/dl)
Normal	81.11 ± 3.70	164.24 ± 2.51	181.20 ± 6.03	1.54 ± 0.08	9.55 ± 0.24
Induced (CCl ₄)	179.23 ± 8.24 [*]	389.22 ± 6.23 [*]	397.34 ± 5.56 [*]	5.63 ± 6.05 [*]	4.56 ± 0.13 [*]
Standard (Silymarin)	81.13 ± 3.50 ^{***}	178.65 ± 4.56 ^{***}	194.15 ± 8.25 ^{***}	1.49 ± 2.46 ^{***}	9.65 ± 4.71 ^{***}
<i>PHAELSS 300</i> mg/kg	95.26 ± 3.68 ^{***}	262.23 ± 4.65 ^{***}	270.15 ± 6.22 ^{***}	1.645 ± 4.33 ^{***}	7.93 ± 3.06 ^{**}
<i>PHAELSS 500</i> mg/kg	79.23 ± 5.67 ^{***}	196.44 ± 8.63 ^{***}	219.43 ± 7.26 ^{***}	1.623 ± 0.23	8.78 ± 0.54

Values are mean ± SEM, n = 6. (One way ANOVA Followed by Dunnette multiple comparisons test). Statistically significance of ** P<0.01, *** P<0.001, when compared with CCl₄ induced group and * P<0.05, when compared ith normal group.

FIGURE 1: EFFECT OF POLYHERBAL ACETONIC EXTRACT OF CURCUMA LONGA RHIZOME AND SIDA SPINOSA LEAVES ON HISTOPATHOLOGICAL DIAGRAM OF LIVER TISSUE IN CCL₄ INDUCED HEPATOTOXIC RATS.



DISCUSSION

There are many factors which are responsible for the liver damage or injuries such as chemicals and drugs. In the present study, CCl₄ was used to induce hepatotoxicity, since it is clinically relevant. Elevated levels of serum glutamic oxaloacetic transaminase (SGOT) and serum glutamic pyruvic transaminase (SGPT) are indications of hepatocellular injury [27].

In CCl₄ induced hepatotoxicity, CCl₄ is metabolized in human cell (endoplasmic reticulum and mitochondria) with the formation of CCl₃O-, the reactive oxidative free radical intermediate generated by cytochrome P450. The nascent oxygen O- resulting from lipoperoxidation causes an increase in intracellular reactive Fe⁺² ions, aldehyde, GSH depletion, and calcium restoration. In addition to direct covalent

contact, oxidative CCl₃ O- causes degeneration of Ca⁺² sequestrations. Failure to sequester leads in increased intercellular Ca⁺², aggregation by proteolytic enzymes, and a rise in Fe⁺² ions, which precipitates aldehyde cytotoxicity through lipid peroxidation [28].

Administration of CCl₄ to experimental animals produced statistically significant rise in the enzymes levels, namely SGOT, SGPT, ACP, ALP, etc indicating the chemical induced hepatocellular toxicity. The inhibitory effect of the *Polyherbal Acetonic extract of Curcuma longa rhizome and Sida spinosa leaves* (300 and 500 mg/kg, p.o.) on hepatotoxicity were compared to that of positive control group. The significant protection in the biochemical parameters like SGOT, SGPT, ACP and ALP against CCl₄ induced elevations in pretreatment of the animals with the *Polyherbal Acetonic extract of Curcuma longa rhizome and Sida spinosa leaves* (300 and 500 mg/kg, p.o.). Further there was increase in weight of the liver treated with the CCl₄ were seen as compared to the normal. The treatment with the *Polyherbal Acetonic extract of Curcuma longa rhizome and Sida spinosa leaves* (300 and 500 mg/kg, p.o.) retains the liver weight near to the normal. Liver section of control rat showing a normal hepatic architecture wall brought about from the central vein. The liver samples of CCl₄ treated rats showed gross necrosis of the centrilobular hepatocytes characterized by gross necrosis, degeneration, karyolysis and eosinophilic infiltration which are significantly prevented by treatment with the *Polyherbal Acetonic extract of Curcuma longa rhizome and Sida spinosa leaves* (300 and 500 mg/kg, p.o.) that showed the hepatoprotective activity. The histopathological pattern of the livers of the rats treated with CCl₄ plus extracts showed minimal necrosis in centrilobular and regeneration of hepatocytes. A number of scientific reports indicated that certain flavonoids, triterpenoids and steroids have protective effect on liver due to its antioxidant properties. Administration of *Polyherbal Acetonic extract of Curcuma longa rhizome and Sida spinosa leaves* (300 and 500 mg/kg, p.o.) that showed significant hepatoprotective activity; while qualitative phytochemical investigations on the *Polyherbal Acetonic extract of Curcuma longa rhizome and Sida spinosa leaves* (300 and 500 mg/kg, p.o.) also showed test positive for flavonoids by chemical tests. Further, it has been reported that the flavonoid constituents of the plant possess antioxidant properties and was found to be useful in the treatment of liver damage [29].

The administration of hepatoprotective drugs may induce the hepatocytes to resist the toxic effect of CCl₄. The results indicated that the *Polyherbal Acetonic extract of Curcuma longa rhizome and Sida spinosa leaves* (300 and 500 mg/kg, p.o.) has significant hepatoprotective activity. The obtained results indicated a high degree of protection against the hepatotoxic effect of CCl₄.

References

1. Singh SS, Pandey SC, Shrivastava S, et al. Chemistry and medicinal properties of *Curcuma longa*. Indian J Pharmacol. 2003; 35: 83-9.
2. Kirtikar KR, Basu BD. Indian Medicinal Plants, Vol 1. 2nd ed. New Connaught Place, Dehra Dun; 1975.
3. Nayampalli SS, Ainapure SS, Samant BD, et al. A comparative study of diuretic effects of *Curcuma longa* and hydrochloro-thiazide in rats and a preliminary phase I study in human volunteers. J Postgrad Med. 1988; 34: 233-6.
4. Aiyer KN, Kolammal M. Pharmacognosy of Ayurvedic Drugs, Series 1. 1st ed. Trivendram: The Central Research Institute; 1963.
5. Raghunathan K, Mittra R. Pharmacognosy of Indigenous Drugs. New Delhi: Central Council for Research In Ayurveda & Siddh; 1982.
6. Nadkarni KM, Nadkarni AK. Indian Materia Medica, Vol 1. 3rd ed. Mumbai: M/S Popular Prakasan Pvt. Ltd; 1976.
7. Zhao TF, Wang X, Rimando AM, et al. Folkloric medicinal plants: *Tinospora sagittata* var. *cravaniana* and *Mahonia bealei*. Planta Medica. 1991; 57: 505.
8. Dhaliwal KS. Method and composition for treatment of diabetes. US Patent 5886029; 1999.
9. Kapil A, Sharma S. Immunopotentiating compounds from *Curcuma longa*. J Ethnopharmacol. 1997; 58: 89-95.
10. Mehrotra R, Katiyar CK, Gupta AP. Hepatoprotective compositions and composition for treatment of conditions related to hepatitis B and E infection. US Patent 749296; 2000.

11. Jana U, Chattopadhyay RN, Shw BP. Preliminary studies on anti-inflammaory activity of Zingiber officinale Rosc., Vitex negundo Linn. and *Curcuma longa* (Willid) Miers in albino rats. Indian J Pharmacol. 1999; 31: 232-3.
12. Anonymous. Wealth of India: Raw materials, Vol X. New Delhi: CSIR; 1976.
13. Sethuraman MG, Lalitha KG, Raj Kapoor B. Hepatoprotective activity of Sarcostemma brevistigma against carbon tetrachloride-induced hepatic damage in rats. Current Science. 2003; 84: 1186-87.
14. Singh RP, Padmavathi B, Rao AR. Modulatory infl uence of Adhatoda vesica (Justica adhatoda) leaf extract on the enzyme of xenobiotic metabolism, antioxidant status and lipid peroxidation in mice. Mol Cell Biochem. 2000; 213: 99-109.
15. Harbone JB. Phytochemical methods - A guide to modern technique of plant analysis, 2nd edn, chapman and hall, Newyork; 1984. 85pp.
16. CPCSEA. (2003) Indian Journal pharmacology 35: 257-274.
17. Ward FM and Daly MJ. (1999) "Hepatic Disease. In: Clinical Pharmacy and Therapeutics (Walker R.and C.Edwards Eds.)". Churchill Livingstone, New York. pp. 195-212.
18. Yoganarasimhan SN. (1996) Medicinal plant of India.vol-1 Karnataka. Interline publishing pvt.ltd, Bangalore, pp 232.
19. Reitman S, Frankel S. (1957) A colorimetric method for the determination of serum glutamic oxalacetic and glutamic pyruvic transaminases. American Journal Clinical Pathology 28: 56–63.
20. Kind PRN, King EJ. (1954) Estimation of plasma phosphatase by determination of hydrolysed phenol with amino-antipyrine. Journal Clinical Pathology 7(4): 322-326.
21. Amour FF D^o, Blood FR, Belden DA. (1965) The manual for laboratory work in Mammalian Physiology. The University of Chicago Press, Chicago, 126-128.
22. Lowry OH, Rosebrough NJ, Farr AL, Randall RJ. (1951) Protein measurement with the Folin phenol reagent. Journal of Biological Chemistry 193: 265–275.
23. Avadhoot V, Rana V. (1991) Hepatoprotective effect of *Vitex negundo* against carbon tetrachloride-induced liver damage. Arch Pharmacy Research 14(1): 96-98.

24. Bhanwra V, Singh V, Khosla V. (2000) Effect of *Azadirachta indica* (Neem) leaf aqueous extract on paracetamol-induced liver damage in rats. Indian Journal of Physiology and Pharmacology 44(1): 64-68.
25. Mankani KL, Krishna V, Manjunatha BK, Vidya SM, Singh SJ, Manohara YN, Raheman A, Avinash KR. (2005) A review of natural products with hepatoprotective Activity. Indian Journal of Pharmacology 37(3): 165-168.
26. Gennaro AR. (1995) Remington: The science and practice of pharmacy, vol. I, 19th ed, Mack Publishing Company, Easton (PA), pp.111.
27. Dunnet CW. (1964) New Tables for Multiple Comparisons with a Control. Biometrics 20: 482-491.
28. Yue M, Yu CH, Ren K, Chen W, Li Y. (2006) Transient elevation of hepatic enzymes in volunteers after intake of alcohol. Hepatobiliary and Pancreatic Diseases International 5(1): 52-55.
29. Zhou Z, Wang L, Song Z, Lambert JC, McClain CJ, Kang YJ. (2003) A critical involvement of oxidative stress in acute alcohol-induced hepatic TNF-alpha production. American Journal of Pathology 163: 1137-1146.